

CASE AND RESEARCH LETTER

Trauma-induced Adult Xanthogranuloma Mimicking Keloid on the Left Nasal Ala

Xantogranuloma del adulto inducido por traumatismo, que remeda queloide en ala nasal izquierda

To the Editor,

A 33-year-old healthy female, nurse, Fitzpatrick phototype IV, presented with a history of a piercing proceeded on the left nasal ala in 2019. She referred multiple local traumas in daily activities, such as accidental adhesion of the piercing to clothes or bath towel. In January 2021, a papule appeared on the same nasal region. The patient repeatedly tried to remove the lesion with a small needle, resulting in local bleeding and progressive growth to a tumor. No other lesions or constitutional symptoms have been described.

Dermatological examination revealed small erythematous-brownish nodule, 1.5 cm diameter, similar to a keloid adjacent to the nasal piercing (Fig. 1). No other injuries have been identified. Dermoscopic analysis indicated a yellow-orange central area surrounded by peripheral erythematous border with fine linear

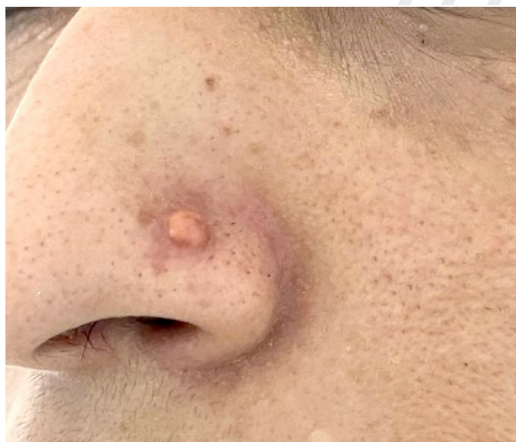

Figure 1 Small erythematous-brownish nodule adjacent to the nasal piercing.

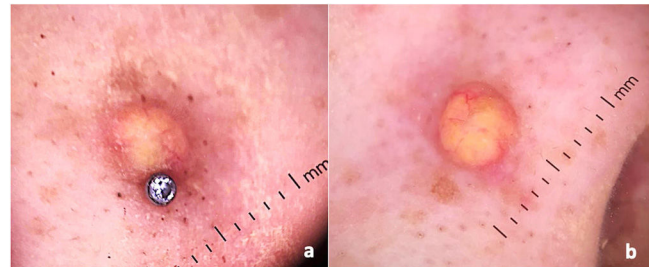

Figure 2 (a and b) Dermoscopic analysis: yellow-orange central area surrounded by peripheral erythematous border with fine linear telangiectasias.

telangiectasias, suggestive of xanthogranuloma (Fig. 2a and b).

We proceeded the complete excision of the tumor. Histopathological study identified a nodular dermal proliferation with xanthomized histiocytes, foreign body-type multinucleated giant cells and Touton multinucleated cells, along with scattered lymphocytes, plasma cells and eosinophils (Fig. 3a and b). Immunohistochemistry appointed positive stains for CD68. S100 and CD1a were absent. BRAF-V600E mutations analysis through real-time polymerase chain reaction (PCR) was negative. Laboratory investigation revealed no abnormalities in routine blood examination parameters, triglyceride levels, liver function or renal function. The tests confirmed the diagnosis of adult xanthogranuloma, and there was clinical improvement after surgical removal. The patient maintains dermatological follow-up with no injury recurrence.

Xanthogranuloma is the most common non-Langerhans cell histiocytosis.¹ It is a benign proliferative disorder, usually described in early childhood as juvenile xanthogranuloma (JXG). Almost 85% of cases of JXG occur in infants less than one year of age, with a male preponderance.¹ Late-onset lesions in adults is infrequent and represents 10% of all xanthogranulomas.¹ Most reports describe adult xanthogranuloma between the third and fourth decades of life, with equal sex distribution.² The pathogenesis is unknown, and the most associated triggers are infections or physical factors,³ with few studies in the world literature describing trauma-induced xanthogranuloma. The patient described in this report presented an unusual onset of adult xanthogranuloma after recurrent local traumas.

<https://doi.org/10.1016/j.ad.2022.01.050>

0001-7310/© 2022 AEDV. Published by Elsevier España, S.L.U. This is an open access article under the CC BY-NC-ND license (<http://creativecommons.org/licenses/by-nc-nd/4.0/>).

Please cite this article as: E. Neves Souza, M. Rodrigues Batalha, L. Horta da Silva et al., Trauma-induced Adult Xanthogranuloma Mimicking Keloid on the Left Nasal Ala, ACTAS Dermo-Sifiliográficas, <https://doi.org/10.1016/j.ad.2022.01.050>

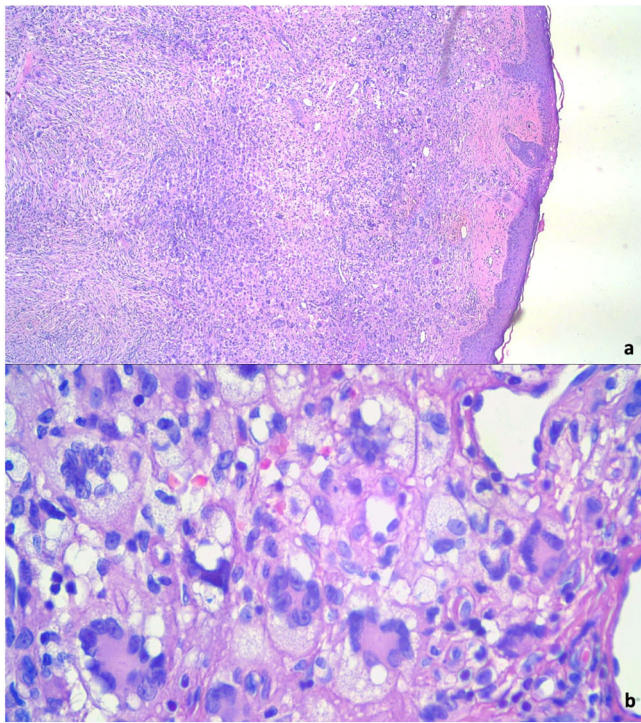


Figure 3 (a) Dense dermal histiocyte infiltrate (HE 100×). (b) Histiocytes and giant multinucleated Touton cells (HE 400×).

The lesion typically manifests as a reddish or yellowish to brown solitary papulonodule on the head, neck, limbs, and upper trunk.⁴ Nasal involvement is even rarer and only three cases on this specific topography have been published.⁵⁻⁷ Tan et al. (2014) also reported an unusual presentation of adult xanthogranuloma on the left nasal ala, as we describe herein. However, unlike our case, no trigger factor has been identified.⁵ A few articles documented multiple lesions and extracutaneous and systemic involvement.^{2,4,8} Dermoscopic evaluation is a powerful tool to define diagnostic hypothesis, revealing the characteristic yellow-orange central area surrounded by a peripheral erythematous border with fine linear telangiectasias.¹ Differential diagnosis includes dermatofibroma, Langerhans cell histiocytosis, other xanthomatous lesions, mastocytoma, and Spitz nevus.

Diagnostic confirmation is made through skin biopsy. Histopathological analysis identifies dense dermal histiocyte infiltrate and Touton giant cells, which are multinucleated cells, with homogeneous eosinophilic cytoplasmic center and peripheral xanthomatization.³ Immunohistochemistry is also important to define diagnosis and shows positive stains for Factor XIIIa, CD68, CD163, CD14, and fascin. Stains for S100 and CD1a, specific for Langerhans cells, are negative.⁹ In cases with atypical histology features or immunohistochemistry suggestive of xanthogranuloma and Langerhans cell histiocytosis (LCH), the investigation of BRAF-V600E mutations is recommended. BRAF-V600E mutations have been described in LCH and can identify LCH coexisting with xanthogranuloma.¹⁰ In this case report, this oncogenic mutation was absent, reaffirming the xanthogranulomatous nature of the tumor.

Usually, no laboratory abnormalities are identified in patients with solitary AXG. However, clinicians should be

aware of systemic involvement and hematological malignancies in adults with multiple xanthogranulomas.⁸ In these cases, laboratory and imaging investigation are essential. AXG generally follows a benign course, with spontaneous regression in approximately 3–6 years.¹ Surgical excision, CO₂ laser, and intralesional steroids can be performed, mainly for cosmetic reasons.³

In this report, the patient's history and clinical examination suggested a keloid lesion. However, dermoscopic analysis revealed typical findings of xanthogranuloma and guided our Dermatology team to an accurate diagnosis. In conclusion, the correct use of the dermatoscope is effective not only to evaluate melanocytic lesions, but also to non-melanocytic, as in the present case. Dermatologists should use this tool daily in every physical examination to improve diagnostic accuracy. After directing the diagnostic hypothesis, the confirmation was established through histopathology and immunohistochemistry, which were also compatible with adult xanthogranuloma.

Conflict of interests

The authors declare that they have no conflict of interest. Q2

References

- Hernández-San Martín MJ, Vargas-Mora P, Aranibar L. Juvenile xanthogranuloma: an entity with a wide clinical spectrum. *Actas Dermosifiliogr (Engl Ed)*. 2020;111:725–33, <http://dx.doi.org/10.1016/j.ad.2020.07.004>.
- Ferreira BR, Cardoso JC, Reis JP, Tellechea Ó. Multiple adult-onset xanthogranuloma, an uncommon diagnosis. *An Bras Dermatol*. 2017;92:294–5, <http://dx.doi.org/10.1590/abd1806-4841.20176216>.
- Chisolm SS, Schulman JM, Fox LP. Adult xanthogranuloma, reticulohistiocytosis, and Rosai–Dorfman disease. *Dermatol Clin*. 2015;33:465–72, <http://dx.doi.org/10.1016/j.det.2015.03.011>.
- Tian X, He S, Li R, Wang J. Multiple adult xanthogranuloma: a rare case report with characteristics. *Asp Biomed Clin Case Rep*. 2021;4:88–92, <http://dx.doi.org/10.36502/2021/ASJBCCR.6235>.
- Tan LC, Tan KB, Aw CW. Unusual presentation of adult xanthogranuloma: a case report. *Singapore Med J*. 2014;55:e25–7, <http://dx.doi.org/10.11622/smedj.2013207>.
- Bourra H, Lemtibbet S, Lamchahab FZ, Saidi A, Senouci K, Hassam B. Xanthogranulome de type adulte de la base du nez [Adult xanthogranuloma at the base of the nose]. *Ann Dermatol Venereol*. 2013;140:835–7, <http://dx.doi.org/10.1016/j.annder.2013.06.007>.
- Adya KA, Inamadar AC, Palit A, Pattar RS. A translucent yellow-brown papule on the nose. *J Cutan Aesthet Surg*. 2019;12:255–7, http://dx.doi.org/10.4103/JCAS.JCAS_37_19.
- Shoo BA, Shinkai K, McCalmont TH, Fox LP. Xanthogranulomas associated with hematologic malignancy in adulthood. *J Am Acad Dermatol*. 2008;59:488–93, <http://dx.doi.org/10.1016/j.jaad.2008.03.046>.
- Sandell RF, Carter JM, Folpe AL. Solitary (juvenile) xanthogranuloma: a comprehensive immunohistochemical study emphasizing recently developed markers of histiocytic lineage. *Hum Pathol*. 2015;46:1390–7, <http://dx.doi.org/10.1016/j.humpath.2015.05.025>.
- Ishikawa M, Endo Y, Uehara A, Suto M, Yasuda M, Motegi SI, et al. Cutaneous adult xanthogranuloma with a

149 small portion of BRAF(V) (600E) mutated Langerhans
150 cell histiocytosis populations: a case report and the
151 review of published work. *J Dermatol.* 2019;46:161-5,
152 <http://dx.doi.org/10.1111/1346-8138.14725>.

Q1 E. Neves Souza^{a,b,*}, M. Rodrigues Batalha^c,
L. Horta da Silva^c, M. Neves Souza^d

^a *Universidade Federal do Espírito Santo (UFES), Vitória, ES, Brazil*

^b *Hospital Universitário Cassiano Antônio Moraes (HUCAM), Vitória, ES, Brazil*

^c *Intituto Izamar Milediú da Silva (IMS), Rio de Janeiro, RJ, Brazil*

^d *Faculdade Multivix, Vitória - ES, Brazil*

* Corresponding author.

E-mail address: neves.emilly@hotmail.com

(E. Neves Souza).

153
154
155
156
157
158
159
160

UNCORRECTED PROOF